

Hepatotoxic Evaluation in Albino Rats Exposed to Ceftriaxone

M.G.A. El-Sayed, A.A. Elkomy and M.H. Aboubakr*

Department of pharmacology, Faculty of Veterinary Medicine, Benha University, Egypt.

E mail : mohamedhafez19@yahoo.com

Abstract

Objective: The aim of the present study was to investigate the hepatotoxic effect and biochemical alterations induced by ceftriaxone in rats.

Methods: Rats were injected ceftriaxone intramuscularly with 180 (therapeutic dose) and 360 (double therapeutic dose) mg/kg b.wt. daily for five consecutive days. Blood and liver samples were collected for quantitative determination of some biochemical parameters and histopathological examination respectively.

Results: Ceftriaxone produced significant increase in serum concentrations of liver enzymes (AST and ALT), total bilirubin, cholesterol, Tg and LDL-cholesterol. Ceftriaxone also caused significant decrease in albumin and HDL-cholesterol. Ceftriaxone injection in the tested doses caused histopathological changes in liver. The severity of these changes was dose dependant.

Conclusion: Hepatic functions should be monitored and/or the dose should be adjusted during ceftriaxone therapy.

Key words: Ceftriaxone, Biochemical, Histopathology, Hepatotoxicity, Rats.

INTRODUCTION

Ceftriaxone is a broad spectrum cephalosporin resistant to various types of beta-lactamases, with potent activity against gram-positive and gram-negative bacteria, including *Enterobacteriaceae*, *Haemophilus influenzae*, *Streptococcus pneumoniae* and other nonenterococcal streptococci, Methicillin-resistant staphylococci, Enterococci, *Pseudomonas aeruginosa* and *Bacteroides fragilis* were typically resistant^[1]. The drug acts through inhibition of transpeptidase enzymes responsible for the final step in bacterial cell wall synthesis^[2] and has broad stability against beta-hydrolysis^[3]. In human medicine, ceftriaxone is widely used, because of its prolonged terminal half-life (5.4-8.2 h) that allows its prescription on a single administration per day basis^[4,5]. Expanded informations concerning the biochemical and liver histopathological changes of ceftriaxone will be of benefits to physicians and their patients. Therefore, the purpose of this study was to investigate the biochemical changes in serum and histopathological changes of the livers during and after administration of ceftriaxone.

The liver is sometimes referred to as the "great chemical factory" of the body, because the body depends on the liver to regulate, synthesize, store and secrete many important proteins, nutrients, chemical and to purify and clear toxin or unneeded substance from the body. Most importantly, the liver is considered to be the center of metabolic transformation of drugs and other toxins entering from the

gastrointestinal tract as such the normal or healthy functioning of the liver determines the health status of an individual^[6]. For this reason, this research on hepatotoxic effects of ceftriaxone had been performed.

MATERIALS AND METHODS

Materials

Ceftriaxone:

Ceftriaxone is a sterile, semisynthetic, broad-spectrum third generation cephalosporin antibiotic for intravenous or intramuscular administration. The chemical formula of ceftriaxone sodium is $C_{18}H_{16}N_8Na_2O_7S_{33.5}H_{20}$. It has a calculated molecular weight of 661.59. Ceftriaxone is a white to yellowish-orange crystalline powder which is readily soluble in water, sparingly soluble in methanol and very slightly soluble in ethanol. The pH of a 1% aqueous solution is approximately 6.7. $C_{18}H_{16}N_8Na_2O_7S_{33.5}H_{20}$ is supplied for intramuscular or intravenous administration in strengths equivalent to 250 mg, 500 mg and 1 g of $C_{18}H_{16}N_8Na_2O_7S_{33.5}H_{20}$. It was produced by Smithkline Beecham for Novartis Pharma Company (Egypt) and has the commercial name Ceftriaxone®.

Laboratory animals

Twenty seven adult male Wistar strain albino rats (150-200 g) were obtained from the Animal House, (DFXOWRI 9 HMUCDU 0 HGFLGH %HQK8 QYHUVW, Egypt). They were maintained on standard pellet diet and tap water ad libitum and were kept in wire cages under a 12 hr

light/dark cycle and room temperature 22-24°C. Rats were acclimatized to the environment for one week prior to experimental use. This investigation was approved by the Animal Research Ethics Committee, Benha University.

Methods

Biochemical effects of ceftriaxone in rats:

Rats were divided in three groups, each of nine rats. First group were injected intramuscularly with saline for 5 days and considered as control group. Rats of the second and third groups were injected intramuscularly with ceftriaxone at dose 180 mg/kg. b.wt. as therapeutic dose (Group A) and 360 mg/kg. b.wt. as double therapeutic dose (Group B), once daily for 5 consecutive days. The blood samples were collected during the 1st, 3rd, 5th days respectively and after drug administration at 7th, 9th, 11th and 13th days from the beginning of experiment. Blood samples were collected from the venous plexus at the medial canthus of the eye by means of capillary tubes the collected blood samples were allowed to clot and serum samples were obtained by centrifugation at 3000 RPM for 15 minutes and then obtained by self aspirating pipette. Serum samples were kept in deep freeze for quantitative determination of AST, ALT, total bilirubin, albumin, cholesterol, Triglycerides, HDL-cholesterol and LDL-cholesterol. One day after the last administration, three rats from each group were sacrificed and the liver of each rat were taken, four days after the last administration another three rats from each group were sacrificed and the

liver of each rat were taken, eight days after the last administration, three rats were sacrificed and the liver of each rat was taken. All livers were preserved in formalin solution for histopathological examination.

Assay kits : AST, ALT, total bilirubin and albumin were determined in serum using kits from Diamond Diagnostic Company, Egypt. While, Cholesterol, Triglycerides, HDL-cholesterol and LDL-cholesterol were determined in serum using kits from in Vitro Scient Company, Egypt. All were measured by spectrophotometer.

Histopathological examination of liver

The preparation of liver samples and procedures of staining were carried out according to^[7].

Statistical analysis:

Data were expressed as mean \pm S.E. and were statistically analyzed using Student t test to express the differences between groups^[8].

RESULTS

The present study was designed to evaluate the effect of ceftriaxone on the liver. The values of serum alanine aminotransferase (ALT), aspartate aminotransferase (AST) and total bilirubin in ceftriaxone treated rats were significantly increased compared to the control group. While serum albumin in treated groups was decreased significantly compared to the control group (Table 1). The effect of ceftriaxone on lipid profile (cholesterol, Triglycerides, HDL-cholesterol and LDL-cholesterol) in rats was summarized in table (2). Histopathological effects of ceftriaxone on livers were shown in (Figure 1).

Table 1: Effect of ceftriaxone on some biochemical parameters in rats.

Parameters	Groups	Days						
		1 st day	3 rd day	5 th day	7 th day	9 th day	11 th day	13 th day
AST (U/L)	Control	52.33 \pm 2.23	52.89 \pm 1.93	48.56 \pm 1.86	55.50 \pm 3.17	58.33 \pm 2.93	51.67 \pm 0.67	49.00 \pm 2.52
	(A)	54.11 \pm 1.90	72.22 \pm 2.38***	70.11 \pm 2.80***	67.33 \pm 1.56**	65.67 \pm 3.00	56.33 \pm 1.20*	50.67 \pm 2.40
	(B)	53.11 \pm 1.69	70.89 \pm 2.76***	71.56 \pm 3.28***	71.33 \pm 3.63**	68.17 \pm 2.55*	62.00 \pm 2.31*	48.67 \pm 2.96
ALT (U/L)	Control	37.33 \pm 1.18	35.00 \pm 1.86	34.89 \pm 1.65	40.83 \pm 1.30	39.33 \pm 1.52	38.00 \pm 1.15	33.33 \pm 1.45
	(A)	35.63 \pm 1.83	53.78 \pm 2.22***	48.56 \pm 1.38***	56.33 \pm 3.45**	38.67 \pm 1.54	40.67 \pm 0.88	35.33 \pm 0.88
	(B)	38.00 \pm 1.46	53.44 \pm 1.79***	47.56 \pm 1.39***	49.83 \pm 1.72**	52.00 \pm 3.03**	49.33 \pm 3.18*	36.00 \pm 2.08
T. bilirubin (mg/dl)	Control	0.49 \pm 0.02	0.50 \pm 0.02	0.49 \pm 0.02	0.54 \pm 0.04	0.51 \pm 0.02	0.58 \pm 0.03	0.48 \pm 0.03
	(A)	0.51 \pm 0.03	0.66 \pm 0.03***	0.71 \pm 0.02***	0.70 \pm 0.04*	0.50 \pm 0.03	0.54 \pm 0.02	0.46 \pm 0.01
	(B)	0.53 \pm 0.02	0.71 \pm 0.04***	0.71 \pm 0.03***	0.75 \pm 0.03**	0.70 \pm 0.04*	0.57 \pm 0.01	0.02 \pm 0.53
Albumin (g/dl)	Control	4.68 \pm 0.23	5.16 \pm 0.22	4.95 \pm 0.21	4.73 \pm 0.22	4.64 \pm 0.16	4.99 \pm 0.28	4.88 \pm 0.10
	(A)	4.82 \pm 0.17	3.70 \pm 0.13***	3.60 \pm 0.14***	3.96 \pm 0.20*	3.90 \pm 0.10**	4.86 \pm 0.21	4.92 \pm 0.10
	(B)	4.91 \pm 0.11	3.45 \pm 0.15***	3.48 \pm 0.13***	3.45 \pm 0.21**	3.70 \pm 0.10**	4.01 \pm 0.04*	4.38 \pm 0.21

* P<0.05

** P<0.01

*** P<0.001

(A): Rats treated with 180 mg of ceftriaxone/ kg.b.wt. (Therapeutic dose).

(B): Rats treated with 360 mg of ceftriaxone/ kg.b.wt. (Double therapeutic dose).

Table 2: Effect of ceftriaxone on lipid profile in rats.

Parameters	Groups	Days						
		1 st day	3 rd day	5 th day	7 th day	9 th day	11 th day	13 th day
Cholesterol (mg/dl)	Control	100.67±2.57	99.82±1.66	100.85±2.11	100.11±2.17	105.35±2.33	102.18±2.46	107.83±3.76
	(A)	102.25±2.36	132.18±3.71***	136.79±4.62***	137.43±5.72***	128.69±3.97***	133.70±6.26**	117.67±1.31
	(B)	110.69±1.98**	141.29±3.91***	130.81±2.57***	128.05±3.63***	119.22±1.91***	142.08±5.53**	129.69±2.64**
Triglycerides (mg/dl)	Control	72.26±2.15	76.64±1.35	81.18±2.23	75.06±1.05	74.09±2.83	69.34±4.40	77.86±3.63
	(A)	76.37±1.37	85.64±2.73**	87.27±2.08	84.31±2.28**	89.17±3.16**	81.02±3.86	90.75±3.68
	(B)	79.15±1.73*	88.40±2.29***	93.19±2.09**	92.21±2.10***	91.24±2.06***	88.08±0.88*	86.86±2.95
HDL-Cholesterol (mg/dl)	Control	58.58±1.72	56.90±1.12	55.29±1.99	58.74±3.11	60.12±1.24	55.52±1.74	56.21±1.90
	(A)	57.85±2.00	49.12±0.73***	45.98±1.17***	64.14±1.72	50.92±1.74***	58.16±1.17	60.92±1.47
	(B)	63.15±1.68	48.08±1.01***	47.93±0.89**	48.62±2.10*	49.77±0.96***	50.23±1.78	61.03±2.19
LDL-Cholesterol (mg/dl)	Control	27.63±2.67	27.59±2.26	29.33±2.47	26.36±4.95	30.41±3.38	32.79±2.11	36.06±6.23
	(A)	29.12±2.66	65.93±3.62***	73.36±3.91***	56.43±6.71**	59.93±3.26***	59.37±7.88*	38.60±2.34
	(B)	31.71±2.95	75.52±4.13***	64.24±2.28***	60.99±3.78***	51.20±2.63***	74.23±4.13***	51.29±3.22

* P<0.05

** P<0.01

*** P<0.001

(A): Rats treated with 180 mg of ceftriaxone/ kg.b.wt. (Therapeutic dose).

(B): Rats treated with 360 mg of ceftriaxone/ kg.b.wt. (Double therapeutic dose).

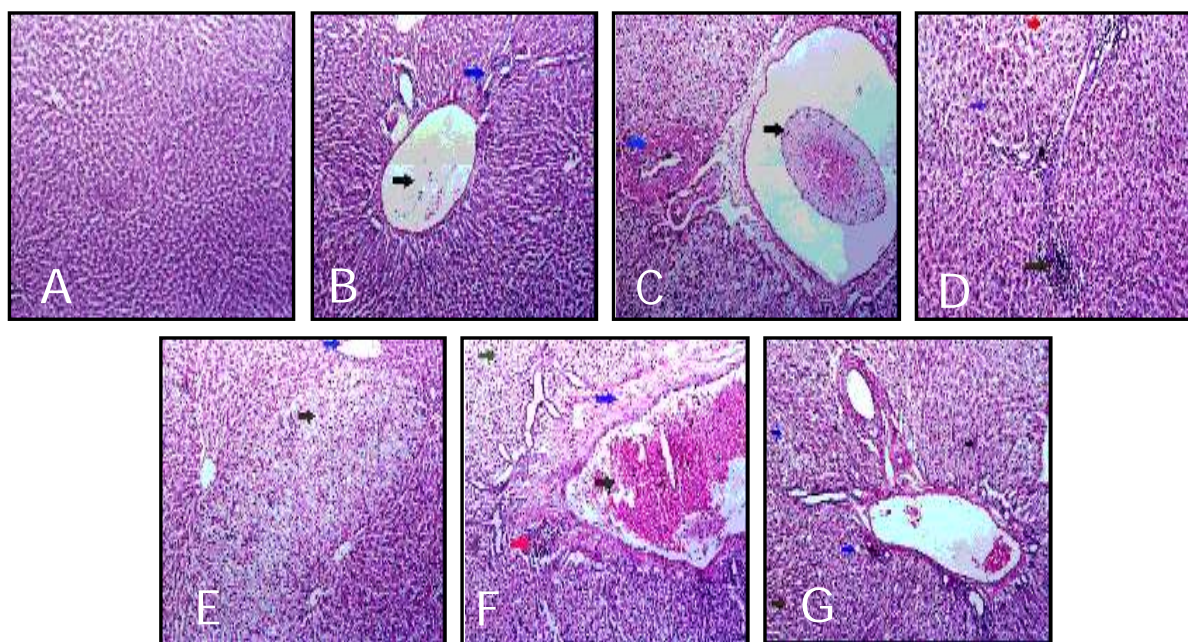


Figure1: Livers of rat administered normal saline, therapeutic (180 mg of ceftriaxone/ kg.b.wt.) and double therapeutic doses (360 mg of ceftriaxone/ kg.b.wt.). The stain was (H & E × 200).

A) Liver of rat administered normal saline showing normal hepatic structure. B) Liver of rat injected with 180 mg of ceftriaxone/ kg.b.wt at 1st day post the last injection showing thrombosis of portal blood vessels with periductal inflammatory cellular infiltration. C) Liver of rat injected with 180 mg of ceftriaxone/ kg.b.wt at 4th day post the last injection showing portal areas revealed congestion and thrombosis of blood vessels with periductal fibrous connective tissue proliferation. D) Liver of rat injected with 180 mg of ceftriaxone/ kg.b.wt at 8th day post the last injection showing periductal inflammatory cellular infiltration mainly macrophage and lymphocytes. Hepatocellular degeneration and regeneration of some hepatocytes. E) Liver of rat injected with 360 mg of ceftriaxone/ kg.b.wt at 1st day post the last injection showing some hepatocytes with cell ballooning in their cytoplasm and congestion of some portal blood vessels. F) Liver of rat injected with 360 mg of ceftriaxone/ kg.b.wt at 4th day post the last injection showing congestion of portal blood vessels, perivascular edema, inflammatory cellular infiltration and hepatocellular degeneration (hydropic). G) Liver of rat injected with 360 mg of ceftriaxone/ kg.b.wt at 8th day post the last injection showing multifocal hemorrhage between hepatocytes and hepatic cellular hydropic degeneration.

DISCUSSION

In the present study, intramuscular injection of ceftriaxone in doses of 180 and 360 mg/kg. b.wt. to rats, produced significant increase in both liver enzymes (AST and ALT) concentrations in serum of treated groups than those recorded in control group. These results were supported by ^[9], who found that, ceftriaxone therapy associated with elevated hepato biliary enzymes and transient biliary stasis. Oral administration of ceftibuten or cefixime in the treatment of complicated urinary tract infections produce slight elevation of serum level of liver transaminase ^[10]. A few cases of high aspartate aminotransferase (ALT) and alanine aminotransferase (AST) levels, along with three cases of hepatitis caused by ceftriaxone were reported ^[11]. Also ^[12] reported a case of drug induced toxic hepatitis in a patient who was treated with ceftriaxone for acute tonsillitis. These results were inconsistent with those obtained by ^[13] who proved that, treatment of rats with cefazolin significantly suppressed activity of alanine and aspartate aminotransferases in serum. Subcutaneous injection of cefazolin to male rats in daily doses of 0.5 2 g per kilogram of body weight significantly decreased alanine aminotranferase and aspartate aminotransferase activities in serum ^[14].

Ceftriaxone produced significant increase in total bilirubin and significant decrease in albumin concentrations in serum of treated groups. The obtained results were similar to those obtained by ^[15], who suggested that, ceftriaxone, which displaced bilirubin from albumin and increased erythrocyte bound bilirubin and unbound bilirubin, should be used with caution in high risk jaundiced newborns. Ceftriaxone and cefoperazone had effect on bilirubin albumin binding, while cefonicid, cefotetan, and cefmetazole competed with bilirubin for albumin binding and, at reported mean peak serum levels, decreased the reserve albumin concentration by 75%, 56%, and 40%, respectively. These five cephalosporins might increase the risk of bilirubin encephalopathy in jaundiced neonates ^[16]. Cefmenoxime competed with bilirubin for albumin binding. The maximal displacement factor for cefmenoxime was 1.10, representing approximately a 10% increase in free bilirubin concentration ^[17]. Immediately after the end of ceftriaxone administration, reserve albumin

concentration decreased from 91.9 (+/- 25.1) $\mu\text{mol/l}$ to 38.6 (+/- 10.1) $\mu\text{mol/l}$. At the same time the plasma bilirubin toxicity index increased from 0.64 (+/- 0.40) before drug infusion to 0.96 (+/- 0.44) ^[18]. A case of 53 year old man who was treated with intravenous ceftriaxone 2 gm every 12 hours. After 7 days of therapy, the patient's liver function test results, including total, direct, and indirect bilirubin levels, increased significantly from baseline, and the patient became jaundiced ^[19]. These results were inconsistent with those obtained by ^[20], who proved that, after administration of ceftriaxone daily into the wing vein of turkey at a dose rate of 50 mg/kg for 4 days, the total bilirubin concentration was decreased in experimental samples in comparison with control.

Ceftriaxone induced significant increase in total cholesterol, triglycerides, low density lipoprotein cholesterol and significant decrease in high density lipoprotein cholesterol concentrations in serum of treated groups than recorded in control group. These results were consistent with those obtained by ^[21] after administration of gentamicin intramuscularly to rabbits at a dose of 80 mg/kg b.wt. per day for 5 days produce significant elevation in serum total cholesterol, triglycerides and low density lipoprotein cholesterol concentrations. On the other hand the high density lipoprotein cholesterol concentration was significantly reduced. Amikacin caused significant elevation in serum total cholesterol, triglycerides and low density lipoprotein cholesterol. Also, it decreased the level of high density lipoprotein cholesterol in amikacin treated rabbits with respect to control group ^[22].

These obtained biochemical changes might be attributed to partial damage of the liver. The histopathological finding in the liver of ceftriaxone treated rats obtained in this study were consistent with those obtained by ^[23], who found that, cefdinir produced mixed inflammatory infiltrate in the portal area with neutrophils, plasma cells, lymphocytes and occasional eosinophils. There are areas of bile ductular injury. Moreover, liver biopsy demonstrated mixed inflammatory infiltrate in the lobule with mild central venulitis and moderate hepatocellular and canalicular

cholestasis. Toxic hepatitis associated with ceftriaxone had been recorded by^[12].

CONCLUSION:

From the present study, it could be concluded that, ceftriaxone caused a transient elevation in some biochemical parameters as (AST, ALT, total bilirubin, Cholesterol, Tg and LDL cholesterol) and transient decrease in albumin and HDL cholesterol concentrations in serum of treated rats. Ceftriaxone was not preferable in patient suffered from hepatic disorders, so must be monitoring the patient which suffering from hepatic affections.

REFERENCES

1. Neu HC, Mergel NJ, Fu KP: Antibacterial activity of ceftriaxone, a beta lactamase stable cephalosporin. *Antimicrobial Agents and Chemotherapy.*, 1981; 19: 414-423.
2. Waxam DJ, Strominger L: *Chemistry and Biology of Beta Lactam Antibiotics.* 1982; York Academic Press, New York, NY.
3. Harold CN: Relation of structural properties of beta lactam antibiotics to antibacterial activity. *Am. J. Med.*, 1985; 79: 213.
4. Zhou HH, Chan YP, Arnold K, Sun M: Single dose pharmacokinetics of ceftriaxone in healthy Chinese adults. *Antimicrobial Agents and Chemotherapy.*, 1985; 27: 192-196.
5. Bourget P, Fernandez H, Quinquis V, Delouis C: Pharmacokinetics and Protein binding of ceftriaxone during pregnancy. *Antibiotic Agents and Chemotherapy.*, 1993; 37: 545-9.
6. Garba SH, Sambo N, Bala U: The effect of the aqueous extract of *Kohautia grandiflora* on paracetamol induced liver damage in albino rats. *Niger J Physiol Sci.*, 2009; 24(1): 17-23.
7. Drury RA, Wallington EA: *Carleton's histopathological technique.* 5th Ed. Oxford University Press, New York, Toronto., 1980; 33-48.
8. Snedecor GW, Cokran WG: *Statistical methods* 7th Ed. The Iowa State University Press, Ames., Iowa, U.S.A. 1980; pp. 39-63.
9. Vega C, Quinby PM, Aspy CB: Hepato biliary abnormalities secondary to ceftriaxone use: a case report. *J Okla State Med Assoc.*, 1999; 432-434.
10. Ho MW, Wang FD, Fung CP, Liu CY: Comparative study of ceftibuten and cefixime in the treatment of complicated urinary tract infections. *J Microbiol Immunol Infect.*, 2001; 34(3): 185-189.
11. Bell MJ, Stockwell DC, Luban NL, Shirey RS, Shaak LS, Ness PM, Wong EC: Ceftriaxone induced hemolytic anemia and hepatitis in an adolescent with hemoglobin SC disease. *Pediatr Crit Care Med.*, 2005; 6(3): 363-366.
12. Peker E, Cagan E, Dogan M: Ceftriaxone induced toxic hepatitis. *World J Gastroenterol.*, 2009; 15(21): 2669-2671.
13. Dhami MS, Drangova R, Farkas R, Balazs T, Feuer G: Decreased aminotransferase activity of serum and various tissues in the rat after cefazolin treatment. *Clin Chem.*, 1979; 25(7): 1263-1266.
14. Feuer G, Balazs T, Farber T, Ilse R: Effect of cefazolin on aminotransferase activity in the rat. *J Toxicol Environ Health.*, 1981; 7(3): 593-606.
15. Gillian J, Gonard V, Dalmaso C, Palixc C: Bilirubin displacement by ceftriaxone in neonates: evaluation by determination of 'free' bilirubin and erythrocyte bound bilirubin. *Journal of Antimicrobial Chemotherapy.*, 1987; 19: 823-829.
16. Robertson A, Fink S, Karp W: Effect of cephalosporins on bilirubin albumin binding. *J. Pediatr.*, 1988; 112(2): 291-294.
17. Onks DL, Harris JF, Robertson AF: Cefmenoxime and bilirubin: competition for albumin binding. *Pharmacol Toxicol.*, 1991; 68(5): 329-331.
18. Martin E, Fanconi S, Kälin P, Zwingelstein C, Crevoisier C, Ruch W, Brodersen R: Ceftriaxone bilirubin albumin interactions in the neonate: an in vivo study. *Eur J Pediatr.*, 1993; 152(6): 530-534.
19. Bickford CL, Spencer AP: Biliary sludge and hyperbilirubinemia associated with ceftriaxone in an adult: case report and review of the literature. *Pharmacotherapy.*, 2005; 25(10): 1389-1395.
20. Saganuwan A: Effects of ceftriaxone on hematological and biochemical parameters of turkey. *Animal Research International.*, 2006; 3(3): 562-565.

21. Abu Spetan KA, Abdel Gayoum AA: Effect of high dietary cholesterol on gentamicin induced nephrotoxicity in rabbits. Arch. Toxicol., 2001; 75(5): 284-290.
 22. Devbhuti P, Sengupta C, Saha A: Studies on amikacin induced lipid profile and peroxidation parameters and their control with ascorbic acid. International Journal of Current Pharmaceutical Research., 2010; 2(3): 76-81.
 23. Chen J, Ahmad J: Cefdinir induced hepatotoxicity: potential hazards of inappropriate antibiotic use. J Gen Intern Med., 2008; 23(11): 1914-1916.
-